



PATIENT

Paco Browne

SPECIES

Canine

BREED

Schnauzer Mix

SEX

MN

AGE

11 y

WEIGHT

15 lb

INTERPRETED BY

Keith Blass, DVM, MS,
DACVIM (Cardiology)

IMAGING PERFORMED BY

Karen Ebersole, DVM,
DABVP

HOSPITAL NAME

Scanvet

REFERRING VET

Dr. McGarvey

INVOICE

DATE

11/17/25

PRESENTING CLINICAL SIGNS

Murmur ausculted bilaterally. Pre-anesthetic evaluation (eyelid mass removal/dental).

ECHOCARDIOGRAPHIC FINDINGS

2D, M-mode, and Doppler study.

Left atrial size is normal. The mitral valve leaflets are mildly thickened and exhibit mild systolic prolapse. A mild to moderate jet of eccentric mitral regurgitation is present. Left ventricular dimensions are normal. Left ventricular systolic function is normal. The aorta and aortic valve are normal. Right atrial and right ventricular dimensions are normal. The tricuspid valve leaflets are mildly thickened, and a mild jet of tricuspid regurgitation is present. TR velocity does not suggest the presence of pulmonary hypertension. The pulmonary artery and pulmonic are normal. No shunting lesions are visualized. No pericardial effusion or cardiac masses are seen.

ECG during echo: Sinus rhythm

LA - 28.0 mm
LVIDd - 29.4 mm
LVIDs - 17.1 mm
FS - 41.8%
RA - 17.6 mm
LVOT - 1.15 m/s
RVOT - 0.79 m/s
TR - 2.03 m/s

ASSESSMENT/RECOMMENDATIONS

Degenerative mitral and tricuspid valve disease - stage B1

This examination demonstrates regurgitation of blood across Paco's mitral and tricuspid valves resulting from degenerative valve disease. The hemodynamic effects of the regurgitations appear to be mild at present, as Paco does not have secondary dilation of any of his cardiac chambers, and his ventricular systolic function is well-preserved. As such, Paco's current risk for the development of clinical signs secondary to his valvular diseases, such as coughing, exercise intolerance, syncope, labored breathing, and abdominal distension, appears to be low.

Paco's cardiovascular risk for general anesthesia is mildly increased based on this exam, therefore, some precautions should be taken in order to minimize this risk. I recommend avoiding the use of alpha-2 agonists in the anesthetic protocol, as well as reducing the IV fluid rate by 25%. If possible, monitoring of heart rhythm, blood pressure, and pulse oximetry are recommended during the procedure.

No therapy is recommended at this stage of Paco's valvular diseases.

A recheck echocardiogram is recommended in 6 months.



PATIENT

Paco Browne

SPECIES

Canine

BREED

Schnauzer Mix

SEX

MN

AGE

11 y

WEIGHT

15 lb

INTERPRETED BY

Keith Blass, DVM, MS,
DACVIM (Cardiology)

IMAGING PERFORMED BY

Karen Ebersole, DVM,
DABVP

HOSPITAL NAME

Scanvet

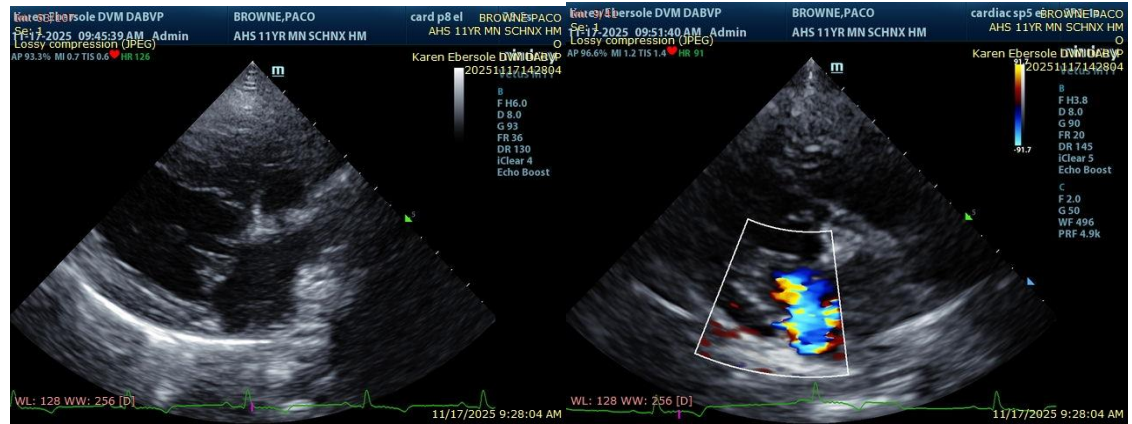
REFERRING VET

Dr. McGarvey

INVOICE

DATE

11/17/25



The information and recommendations provided are based on the images presented by the referring veterinarian/sonographer. No evaluation can be communicated regarding pathology that was not visible in the image/video clips provided.

Thank you for this referral. If the clinical or image interpretation does not parallel your findings or if I can be of any further assistance please contact me.

Keith Blass, DVM, MS, DACVIM (Cardiology)

info@SonoPath.com